

Fetal neurological disorders where doppler solved the riddle: A series of three independent cases

Tina Verma¹, Prashant Jauhari²

¹Fetal Medicine Unit, Cloudnine Hospital, New Delhi, ²Child Neurology Division, Department of Pediatrics, AIIMS, New Delhi, India
(Correspondence: drtinaverma@gmail.com)

Introduction

Fetal neurosonogram with color Doppler has revolutionized antenatal diagnosis of neurological disorders.

We present a series of three independent cases where doppler solved the riddle for us.

Case 1

A 34+3-week primigravida was referred to us with sonographic findings of cardiomegaly, fetal growth restriction (FGR) and oligohydramnios.

Repeat ultrasonographic examination (Fig 1) revealed a 30+4 weeks fetus with severe FGR, oligohydramnios and doppler compromise.

MCA doppler showed redistribution of flow.

Cranial examination revealed a central midline tubular anechoic structure extending posteriorly which on doppler examination appeared to be in continuity with sagittal sinus having turbulent arterial and venous flow suggesting ectasia of the vein of Galen (VOG) confirming the diagnosis of VOG malformation

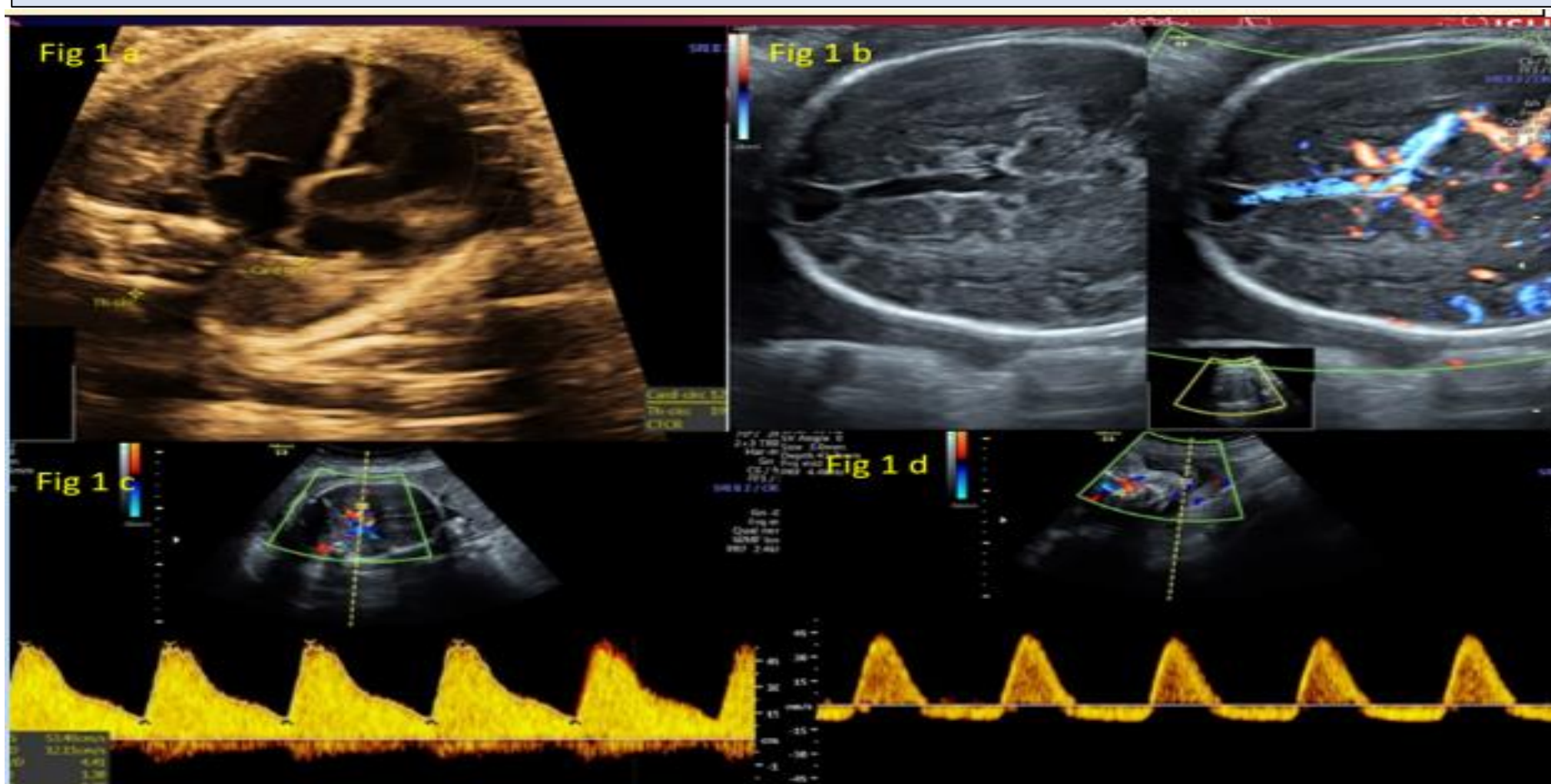


Fig1a-Apical 4 ch showing cardiomegaly; Fig1b-axial view of skull showing ectasia of VOG; Fig 1c- spectral doppler showing MCA redistribution; Fig 1d- Umbilical vein spectral doppler showing reversal in end diastolic flow

Case 2

A primigravida at 26 weeks of gestation was referred with a diagnosis of intracranial teratoma.

The USG examination (Fig 2) revealed a heterogenous space occupying lesion present in the right parietal region measuring 44 x 31 mm with midline shift.

The lesion had smooth margin with cystic areas and peripheral enhancement, with few calcifications within it.

There was no vascularity noted on doppler raising a suspicion of a hemorrhage rather than a solid lesion.

A diagnosis of subdural hemorrhage was made which was later confirmed on fetal MRI and follow up postnatal MRI (Fig 3).

Fig 3A: Fetal MRI (30 weeks)- Large Extra-axial hematoma with midline shift prominent venous channel in Right frontal PIAL Location with probability of PIAL AVF.

Fig 3B: Postnatal MRI (day 8) -Concavo-convex subdural collection along right fronto-parietal region with interhemispheric extension. Venous channel in pial location

Fig 3c: Follow up MRI (1 year)-Cystic encephalomalacia in right fronto-parietal region

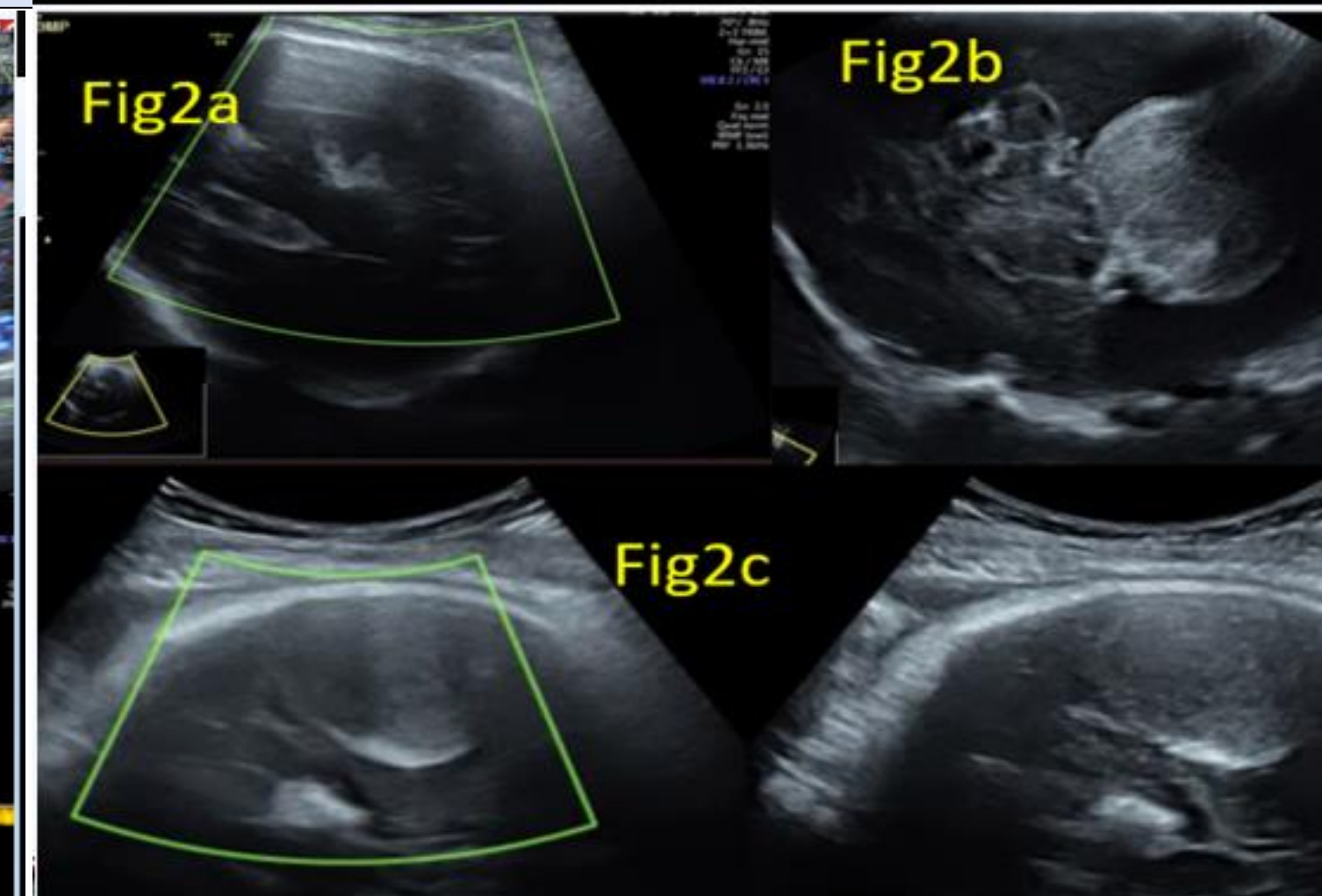


Fig 2a-axial view of skull showing mixed echogenicity lesion without any colour doppler pick up; Fig 2b- axial view of skull showing Echogenic lesion with smooth margins; Fig 2c-Simultaneous colour doppler examination showing no vascularity and distal peripheral enhancement,

Case 3

A G2P1 female was referred at 29 week of gestation with the diagnosis of corpus callosal (CC) dysgenesis.

On fetal neurosonography (Fig 4), absence of posterior part of CC with colpocephaly was noted.

Color doppler evaluation revealed unilateral paramedian tortuous and high velocity flow in circle of Willis with arterial waveform in spectral doppler suggestive of Aneurysm in circle of Willis.

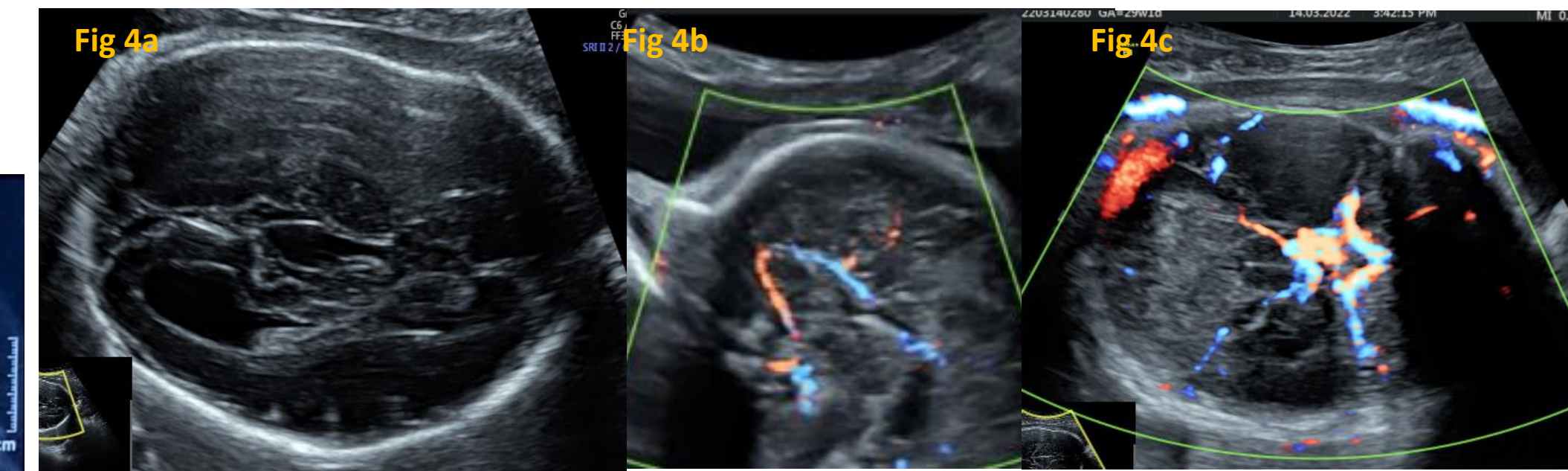


Fig 4a-Axial section of skull showing non visualization of Anterior complex , Fig 4b- Midsagittal section of fetal brain showing abnormal course of pericallosal artery.Fig 4c-Axial section with colour doppler showing vascular aneurysm in circle of willis.

Conclusion

Color doppler revised the diagnosis in all the above cases highlighting the importance of intracranial dopplers in evaluation of fetal brain.

Case 1 underwent embolization on day 08 of life (Bicetre score 8)

Case 2: At 6 years of age: mild residual weakness with focal seizure in remission

Case 3: Postnatal follow up not available